



PATIENT

Jackson Klimovitz

SPECIES

Canine

BREED

American Bulldog/
Boxer Mix

SEX

MN

AGE

2009

WEIGHT

75lbs

INTERPRETED BY

Maggie Machen
Lamy, DVM, DACVIM
(Cardiology)

HOSPITAL NAME

Stay Pet Veterinary

REFERRING VET

Dr. Klimovitz

PRESENTING CLINICAL SIGNS

History: Recheck echo. Anesthetic procedure for mass removal planned pending echo. History of IBD.
-Current medications: Pimobendan 10mg AM, 5mg PM, Budesonide 1mg SID.
-Sedation used: Not needed.
-Pertinent previous ultrasound results: (11/3/20 MML): Trace/mild MR, borderline LAE, mild LVE, moderate systolic dysfunction, FS: 20%, trace TR. LA: 3.5, LV: 5.0/4.0.
-STAT: Not requested.

ECHOCARDIOGRAM FINDINGS

2D, m-mode, color flow and doppler imaging is available. Mild diffuse thickening of mitral valve leaflets with no prolapse into the left atrial lumen. Mild anterior-directed mitral regurgitation with no left atrial enlargement. Normal MR velocity. Mild LV dilation with moderate systolic dysfunction. The tricuspid valve appears subjectively normal, with trace tricuspid regurgitation. Normal velocity. Normal right atrial and ventricular diameter and morphology indicating no overt evidence of pulmonary arterial hypertension. The pulmonic and aortic valves are normal in morphology and mobility. Normal pulmonic and aortic outflow velocity- laminar flow. Trace aortic insufficiency. No pericardial or pleural effusion noted. No cardiac tumors observed.

CARDIAC CHART

| CANINE CARDIAC PARAMETERS | MR VMAX (m/s) | TR VMAX (m/s) | LA/AO (Boon method) | LA/AO (Heart Base; Swe) | FS (%) | EF (%) | EPSS (cm) |
|---|---------------|---------------|---------------------|-------------------------|---------------------------------|--|--|
| NORMAL PARAMETER | 4.5-5.5 | <2.7 | 1.3 | <1.6 | 28-40 | 40-100 | <0.6 |
| PATIENT | 5.6 | 2.5 | NM | 1.3 | 22 | 44 | NM |
| CANINE CARDIAC PARAMETERS | HR (BPM) | AV VMAX (m/s) | PV MAX (m/s) | BODY WEIGHT (kg) | LA 2D short axis Base view (cm) | LVIDd Avg; 2D and m-mode short axis (cm) | LVIDs Avg; 2D and m-mode short axis (cm) |
| NORMAL PARAMETER | 50-100 | 0.7-1.7 | 0.7-1.6 | BELOW | BELOW | BELOW | BELOW |
| PATIENT | 104 | 1.5 | 0.6 | 34.0 | 3.2 | 5.0 | 3.9 |
| *Normal chamber parameters expressed as a mean value (SD) | | | | 3 | 1.27 (5.3) | 2.46 (2.46) | 1.36 (5.5) |
| BODY WEIGHT DEPENDENT PARAMETERS | | | | 5 | 1.40 (4.5) | 2.74 (5.2) | 1.60 (4.7) |
| <i>*Note: All measurements based upon multi-modal images and methods. An average value is reported.</i> | | | | 10 | 1.50 (3.8) | 3.27 (3.5) | 2.06 (3.1) |
| | | | | 15 | 1.83 (2.0) | 3.71 (2.4) | 2.43 (2.1) |
| | | | | 20 | 2.02 (1.9) | 4.14 (2.2) | 2.80 (2.0) |
| | | | | 25 | 2.18 (2.4) | 4.48 (2.9) | 3.10 (2.5) |
| | | | | 30 | 2.33 (3.3) | 4.83 (3.9) | 3.39 (3.4) |
| | | | | 35 | 2.48 (4.3) | 5.17 (5.0) | 3.69 (4.5) |
| | | | | 40 | 2.62 (5.2) | 5.48 (6.1) | 3.96 (5.4) |
| | | | | 50 | 2.88 (7.1) | 6.07 (8.3) | 4.46 (7.4) |

Adapted from June Boon, Veterinary Echocardiography, 1998
Rishniw M and Hollis NE, J Vet Intern Med 2000; 14:429-435
Hansson et al, Vet Rad and Ultrasound 2002
Bonagura et al. Echocardiography: principles of interpretation, Vet Clin North Am 15:1177, 1995

INVOICE

21173

DATE

9/22/21

INTERPRETATION OF THE FINDINGS & FURTHER RECOMMENDATIONS

Compared to the prior study, the overall disease remains stable. The LV dimensions are similar to previous with no progression in LV dilation or dysfunction. The MR is slightly increased comparatively; however, the LA is unchanged. Finally, a small aortic leak is noted which was not previously documented and lifelong blood pressure monitoring is advised. No additional issues are seen.

Given these findings, no additional medications are indicated and continue Pimobendan as previously recommended. Monitor for development of a worsening murmur, cough, labored breathing, exercise intolerance or collapse episodes. Omega fatty acid supplementation may be of some long-term benefit.

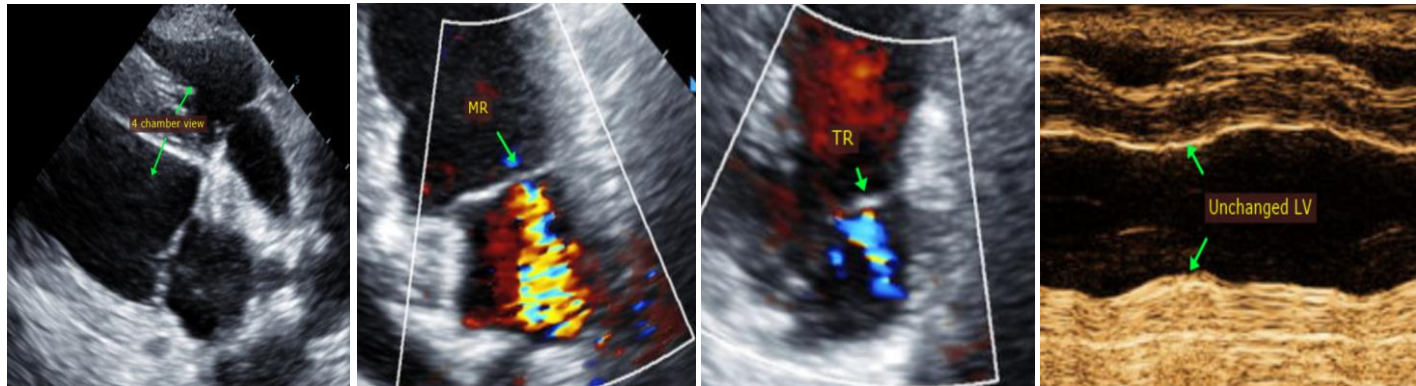
Anesthetic risk remains mild. Cardiac protective drug choices (opioid/benzodiazepine premedication, propofol or alfaxalone induction, isoflurane gas) are recommended. Pre-oxygenate for 5-10 minutes prior to induction. Monitor for arrhythmias, hypotension, and hypoxia both intra and post-operatively and intervene as necessary. Mild IV fluid restriction is recommended to avoid fluid overload. Avoid heart rate stimulating drugs such as atropine unless clinically indicated.

PLAN

Continue Pimobendan as prescribed.

Monitor BP and echocardiogram every 6-8 months to monitor for progression, sooner if any development of clinical signs.

IMAGES



The information and recommendations provided are based on the images presented by the referring veterinarian. No evaluation can be communicated regarding pathology that was not visible in the image/video clips provided.

Thank you for this referral. This report was generated using transcription software, and minor dictation errors may be present. If the clinical or image interpretation does not parallel your findings or if I can be of any further assistance, please contact me.

Maggie Machen Lamy, DVM
Diplomate of the American College of Veterinary Internal Medicine (Cardiology)
info@sonopath.com